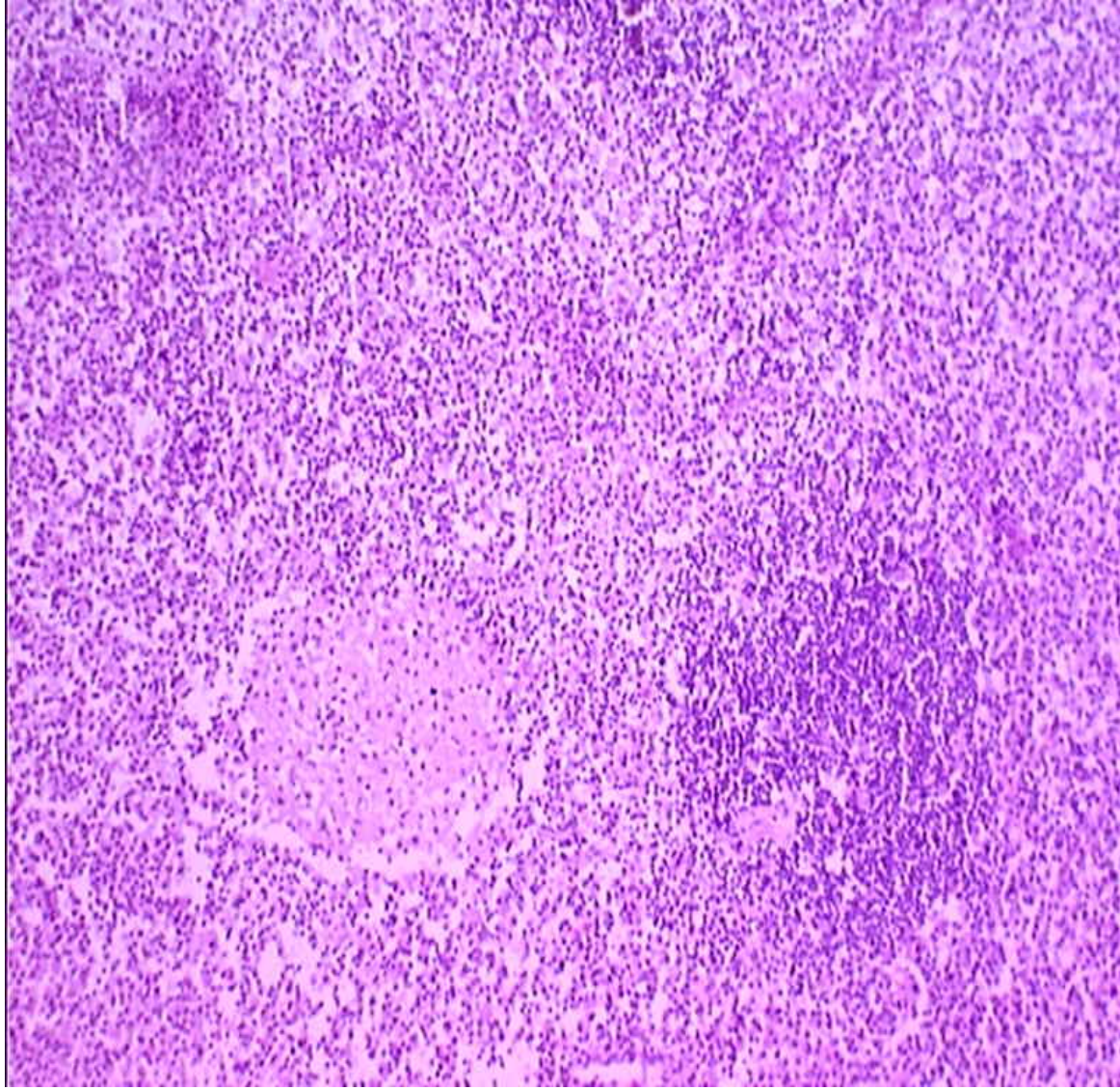


Case of

(do you want the diagnosis?)

- 13 y. old male with acute onset of disease
- fever up to 40C, diarrhea, vomiting, malaise, hepatosplenomegaly were detected
- For a month different infection disease were suspected but without any laboratory proof.
- CT scan revealed prominent enlargement of paraortic lymph nodes.
- But for biopsy mesenteric l/n was taken
- L/n was friable and only fragments were obtained through laparoscope

Effaced structure of lymph node with histiocytic proliferation and scattered follicles



a lot of
histiocytes,
admixed with
lymphocytes
and some
plasma cells

